



GLOBAL JOURNAL OF MEDICAL RESEARCH: A
NEUROLOGY & NERVOUS SYSTEM
Volume 23 Issue 2 Version 1.0 Year 2023
Type: Double Blind Peer Reviewed International Research Journal
Publisher: Global Journals
Online ISSN: 2249-4618 & Print ISSN: 0975-5888

Seizure, an Explosive effect of a Lightning Strike: A Case Report

By Abdellatif Chlouchi, Ilyass Hmadate, Khalil Chafi, Mustapha Rafai, Oussama Outaghyame, Abdellatif Benabbouha, Aziz Bazine & Abderrahmane Elhjouji

Abstract- Lightning strike injuries have a high morbidity rate because of critical alterations of the circulatory system, respiratory system, and central nervous system. Most lightning-related deaths occur immediately after injury because of arrhythmia or respiratory failure.

We describe the case of a patient who experienced a seizure and respiratory distress secondary to a lightning strike and how we obtained a return of spontaneous circulation and intact neurological survival.

We discuss furthermore the pathophysiology of lightning injuries, prognostic factors of favorable outcome of such uncommon accident.

Keywords: seizure, lightning, injury, (aeronautics), management, prevention.

GJMR-A Classification: DDC Code: 612.17 LCC Code: QP111.6



Strictly as per the compliance and regulations of:



© 2023. Abdellatif Chlouchi, Ilyass Hmadate, Khalil Chafi, Mustapha Rafai, Oussama Outaghyame, Abdellatif Benabbouha, Aziz Bazine, & Abderrahmane Elhjouji. This research/review article is distributed under the terms of the Attribution-NonCommercial-NoDerivatives 4.0 International (CC BY-NC-ND 4.0). You must give appropriate credit to authors and reference this article if parts of the article are reproduced in any manner. Applicable licensing terms are at <https://creativecommons.org/licenses/by-nc-nd/4.0/>.

Seizure, an Explosive effect of a Lightning Strike: A Case Report

Abdellatif Chlouchi ^α, Ilyass Hmadate ^σ, Khalil Chafi ^ρ, Mustapha Rafai ^ω, Oussama Outaghyame [¥],
Abdellatif Benabbouha [§], Aziz Bazine ^x & Abderrahmane Elhjouji ^v

Abstract- Lightning strike injuries have a high morbidity rate because of critical alterations of the circulatory system, respiratory system, and central nervous system. Most lightning-related deaths occur immediately after injury because of arrhythmia or respiratory failure.

We describe the case of a patient who experienced a seizure and respiratory distress secondary to a lightning strike and how we obtained a return of spontaneous circulation and intact neurological survival.

We discuss furthermore the pathophysiology of lightning injuries, prognostic factors of favorable outcome of such uncommon accident.

Keywords: seizure, lightning, injury, (aeronautics), management, prevention.

I. INTRODUCTION

Lightning is an aerial electrical discharge, accompanied by a bright light (flash) and a violent detonation (thunder). Lightning is the passage of current through the human body or an animal. In general, a complete lightning strike lasts from 0.2 to 2 seconds.

The electrical parameters of the discharge are the intensity which can reach values higher than 200 000 amperes. The voltage seems to be in the range of 10 to 100 million volts. The temperature can reach 30,000 °C. [1]

A lightning strike can result in significant damage to the human body through three main mechanisms: cardiac arrest, inhibition of respiratory centers and brain damage.

We describe in this case report the circumstances of a lightning strike of a patient on the landing field of the airport of Bunia who sheltered under an airplane whose major clinical manifestation was a generalized seizure and we discuss the modalities of management and prevention of such a particular accident.

a) Clinical case

We received on Sunday the 22nd of January 2023 around 12H40 p.m., at MONUSCO Level 2 Hospital of

Bunia, Democratic Republic of Congo, Mr M.P a 38-year-old man with no medical history for a sudden loss of consciousness and seizures after a thunder lightning strike at 11 a.m. when working in maintenance of a plane at Bunia airport.

When it was raining heavily, the patient took shelter under the wing of the plane where a lightning strike occurred. The electric shock was transferred to the patient and he suddenly fell to the ground and presented a generalized seizure with loss of urine, which stopped spontaneously after thirty seconds.

The patient was immediately transferred to our hospital by the fire fighters team present at the scene.

Initial clinical assessment found an unconscious patient with a GCS of 9/15. Pupils were equal and reactive. There were no ongoing clinical seizures and there was no evidence of head trauma on clinical examination.

He otherwise presented with stertorous breathing, with desaturation at 82% on room air and polypnea at 35 cycles per minute, auscultation finds right ronchi with signs of pulmonary aspiration.

He was hemodynamically stable with blood pressure at 142/83 mmHg, and tachycardia at 126 bpm. The pulses were present and symmetrical, and cardiac auscultation was normal.

The abdomen was soft, there was no external burning and the rest of the clinical examination was without abnormalities, the temperature was 37°C and the capillary blood glucose was 1.6 g/l.

After conditioning and monitoring, the patient was placed in a half-seated position with oxygen therapy through a high concentration mask at 10 liters per minute and a peripheral venous line was taken with 500 ml of isotonic saline.

The patient became agitated which led us to administer 2 mg of Midazolam IV and analgesia with 1 g of Paracetamol in slow infusion.

The EKG was without abnormalities, with a regular sinus rhythm at 87 bpm without repolarization or conduction disorders. (Figure 1)

Chest X-ray showed a small basal alveolar image on the right, consistent with gastric aspiration. (Figure 2)

An abdominopelvic ultrasound in search of a peritoneal effusion or a lesion of a solid organ was without abnormalities.

Author ^{α σ ρ ¥ § χ v}: Moroccan Level 2 Hospital Of Bunia, Mission de l'organisation des Nations Unies pour la stabilisation en RD Congo (MONUSCO), Democratic republic of Congo.

e-mail: drchlouchi.rea@gmail.com

Author ^ω: Air medical evacuation team (AMET) MONUSCO, Bunia, DRC.

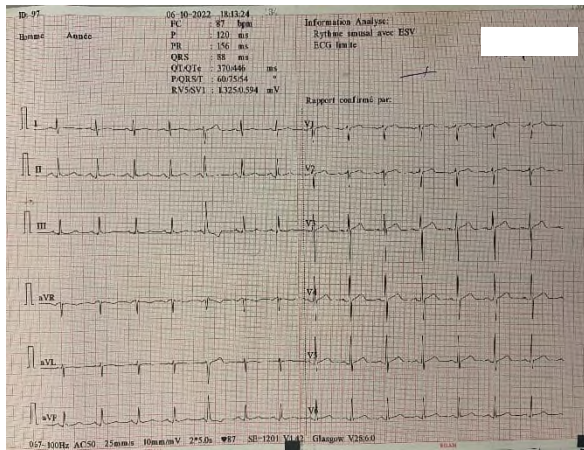


Figure 1: Normal EKG of the Patient

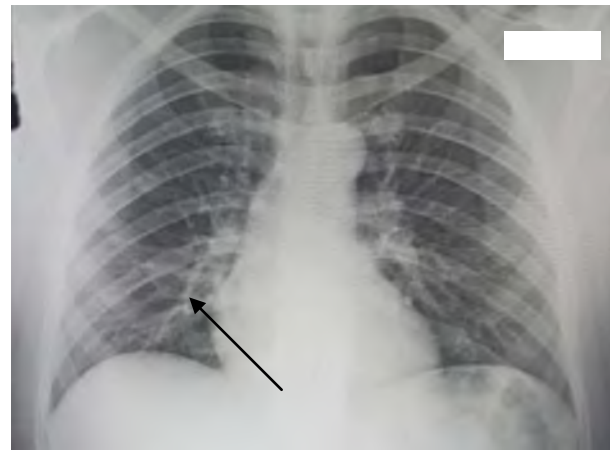


Figure 2: Right basal Image on Chest X-Ray

The patient became increasingly calm and cooperative with total amnesia of the circumstances of the accident.

Blood exams showed hemoglobin at 16.4 g/dl, hematocrit at 49.2%, white blood cells at 11400/ml and platelets at 207000/ml.

The blood ionogram showed a Natremia of 133 mmol/l, a Kalemia of 3.7 mmol/l, a Chloremia of 111 mmol/l, a Bicarbonate of 24 mmol/l and a Phosphorus of 5.5 mg/l.

Blood glucose was = 1.1 g/l, urea 0.7 g/l and creatinine 11mg/l.

The hepatic enzymes was normal with AST at 61 IU/l, ALT at 30 IU/l, total Bilirubin at 14 mg/l, PAL at 70 IU/l, GGT at 67 IU/l and Albumin at 32g/l.

Muscle enzymes and lipasemia were normal.

Troponin was normal at 0.5 ng/ml.

A computerized tomography scan of the head was obtained and was normal, including normal gray-white differentiation, no hemorrhage, or mass effect.

He had pain and paresthesias in both lower limbs, which is why he was put under paracetamol analgesia and under amoxicillin clavulanic acid for aspiration.

After few hours, he was fully conscious and was able to eat and drink. The patient was discharged from the hospital on the third day. He was able to ambulate and had a normal neurological examination and normal mental status. He was awake and able to follow commands.

The patient was referred to a higher level hospital in the capital Kinshasa for further examination and psychological assessment.

II. DISCUSSION

Lightning strikes are a serious accident with a high morbidity and mortality rate. If one out of three

lightning victims dies, seven out of ten survivors have permanent repercussions that are often disabling. However, evidence of lightning injuries is restricted to case reports and nonsystematic reviews. [1]

A distinction must be made between the direct and indirect effects of lightning strikes. Direct effects are due to the release of thermal, light and sound energy but differ according to the type of lightning strike. [2]

When the current crosses the heart, it can cause cardiac arrest by asystole or ventricular fibrillation, myocardial ischemia or rhythm disorders. The danger depends on the intensity of the current, its duration and the time of passage in relation to the cardiac cycle.

When the current crosses nerve structures, it can cause consciousness and neurovegetative disorders.

This can lead to deep coma and immediate or delayed respiratory arrest, from minutes to hours. [3]

The frequency of cephalic burns attests to the frequency of cephalic passage of the current.

The neurological manifestations of a lightning strike are extremely varied. They can be serious cerebral lesions such as cerebral haemorrhages with extradural, subdural or intracranial haematoma, secondary to projections and to the effects of the "blast" on the brain, or temporary symptoms such as loss of consciousness, anterograde amnesia or also anxiety, agitation, irritability, apathy, headaches, cranial nerve damage, paresis or transient paralysis. These symptoms disappear within hours or months. [4]

The respiratory distress is due to the sideration of the respiratory centers by the passage of the current.

The passage of current can also cause electrothermal burns. The muscular masses and the vascular-nervous axes are particularly exposed. The electrical resistance of the latter being low, the intensity delivered locally is high.

For indirect effects, thermal and mechanical energy is released near the lightning channel producing

the same effects as an explosion: burns and/or barotrauma.

It is also necessary to point out the post-traumatic stress disorder, sometimes very disabling.

From an electrical point of view, when the discharge crosses the body and the intensity reaches a peak of about 1,000 amps, the potential difference between the head and the feet reaches 300,000 volts. The total duration of a lightning strike is on average 10 to 20 milliseconds. The bypass arc and the brevity of the electrification have a life-saving effect. [5]

In our case, the major clinical manifestation was seizures followed by a post-critical coma after transfer of the electric current through the cephalic extremity of the patient who sheltered directly below the aircraft's wing.

All airplanes are equipped with lightning protection devices that discharge any electrical build-up conducting the current through the metal hull to the outside which transmitted it to the patient in our case. [6]

The management of these victims is not specific but all aspects of management must be considered. Consequently, the initial clinical assessment must be exhaustive, and the management complete.

The lightning victim is often electrically shocked, burned, injured, possibly polyfractured or even polytraumatized, sometimes hypothermic and psychologically shocked. [7]

The treatment of each injury is essentially symptomatic. The management of a cardiac arrest is not specific. Cardiopulmonary resuscitation is usually prolonged, especially if it could be initiated early, because of the good prognosis of cardiac arrest in these circumstances and the frequent hypothermia. [8]

In our patient, the management consisted of treatment of the seizure and management of respiratory distress and recovery was rapid and complete.

Prevention remains the most effective way to fight against these serious accidents, especially in tropical regions particularly exposed to a high frequency of thunderstorms. The most effective means of this prevention is to take refuge as soon as possible in a raise awareness of the potential dangers of lightning. [9]

III. CONCLUSION

Lightning strikes have high morbidity and mortality rates. However, evidence of lightning injuries is restricted to case reports and series and nonsystematic reviews.

Most damage from lightning injuries is cardiovascular and neurological, although an individual can experience complications with any of their vital functions.

It is vital that every lightning strike patient is treated according to standard trauma guide- lines, with

a specific focus on the possible sequel of lightning injuries.

All health-care professionals should acknowledge the risks and particularities of the lightning strike injuries to optimize the care and outcomes of these patients.

Declarations of Competing Interest

None.

Source of funding

No funding was received.

REFERENCES RÉFÉRENCES REFERENCIAS

1. The Explosive Effects of Lightning: What are the Risks? Blumenthal R. Acad Forensic Pathol. 2016 Mar;6(1):89-95. doi: 10.23907/2016.008. Epub 2016 Mar 1. PMID: 31239875; PMCID: PMC6474511.
2. A clinical review of lightning injuries highlighting pitfalls and a treatment protocol. Van Ruler R, Eikendal T, Kooij FO, Tan ECTH. A shocking injury: Injury. 2022 Oct;53(10):3070-3077. doi: 10.1016/j.injury.2022.08.024. Epub 2022 Aug 17. PMID: 36038387.
3. Brulure par Foudre. A Propos d'une Observation. Mradmi W, Fassi-Fihri J, Mehaji G, Ezzoubi M, Diouri M, Bahechar N, Boukind EH. Ann Burns Fire Disasters. 2005 Sep 30;18(3):127-9. French. PMID: 21990993; PMCID: PMC3187985.
4. Cardiac Arrest Secondary to Lightning Strike: Case Report and Review of the Literature. Rotariu EL, Manole MD. Pediatr Emerg Care. 2020 Jan;36(1):e18-e20. doi: 10.1097/PEC.0000000000001255. PMID: 28767532.
5. A 26-year-old man struck by lightning. Geary SP, Spencer T, Tilney PV. Air Med J 2015;34:8-11 .
6. Management of multi-casualty incidents in mountain rescue: evidence-Based guidelines of the International Commission for Mountain Emergency Medicine (ICAR MEDCOM). Blancher M, Albasini F, Elsensohn F, Zafren K, Hölzl N, McLaughlin K, et al. High Alt Med Biol 2018;19:131-40 .
7. Keraunoparalysis: what a neurosurgeon should know about it? Kumar A, Srinivas V, Sahu BP. J Craniovertebr Junction Spine 2012;3:3-6 .
8. Lightning injuries. Stat pearls Jensen JD, Thurman J, Vincent AL., Treasure Island (FL): StatPearls Publishing LLC; 2021. StatPearls Publishing Copyright © 2021.
9. Wilderness neurology. Schlein SM, Marcolini PG, Marcolini EG. Semin Neurol 2019;39:137-48 .